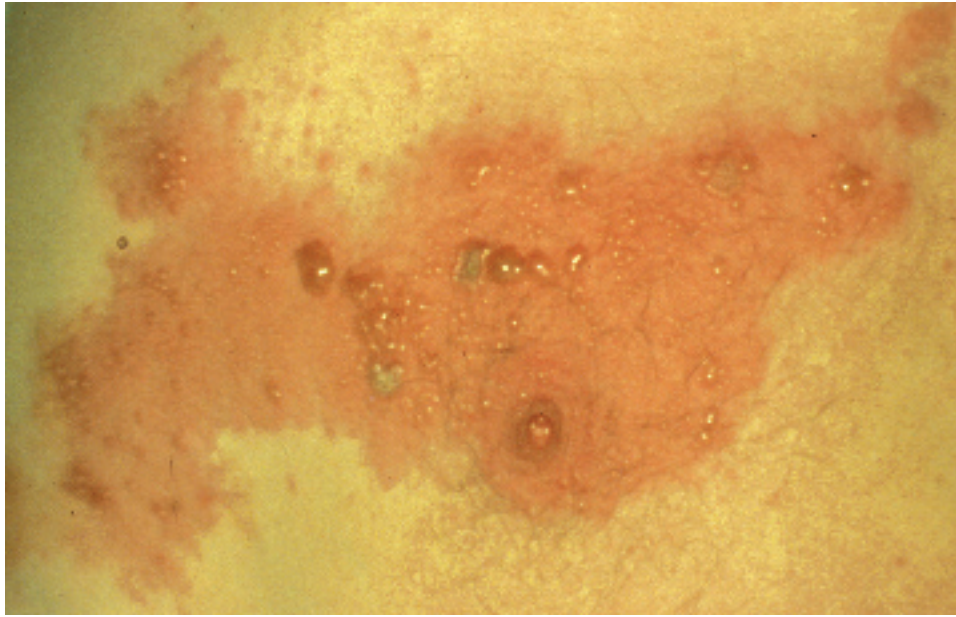

Herpes Zoster (Shingles)

Jessie McCary, MD

Infection with varicella-zoster virus (VZV) causes two distinct clinical syndromes: primary varicella infection (chickenpox) and herpes zoster (shingles). Herpes zoster will be discussed in this chapter. Varicella infection is discussed in a separate chapter.

Once a person has had chickenpox, VZV lies dormant in the human body for decades before reactivating to cause a localized skin eruption in the distribution of one or two dermatomes. The typical lesions of shingles are painful red blisters (or vesicles) that occur on one side of the body and do not cross the midline. The zoster lesions erupt for several days and go through stages of healing over the course of 2-4 weeks.

The likelihood of occurrence and severity of this illness are related to each person's underlying health status. Elderly and immunosuppressed (people are at highest risk of VZV reactivation, and the resulting illness is often more severe. Antiretroviral medications, if given early in the course of illness, can decrease the severity and duration of symptoms and reduce the complications of herpes zoster.

Prevalence and Distribution

The cumulative lifetime incidence of herpes zoster is estimated to be 10-20% of the population. The majority of cases occur in the elderly, with both sexes affected equally. This infection seems to occur less often in African-American people than white populations, as evidenced by a study of elderly people in North Carolina. Approximately 4% of patients who develop herpes zoster will experience

a recurrence.

Immunocompromised individuals, including transplant recipients, HIV-infected patients, and patients receiving long term steroids, are at higher risk of developing herpes zoster than the general population, and these patients are more likely to have disseminated disease and recurrence of shingles.

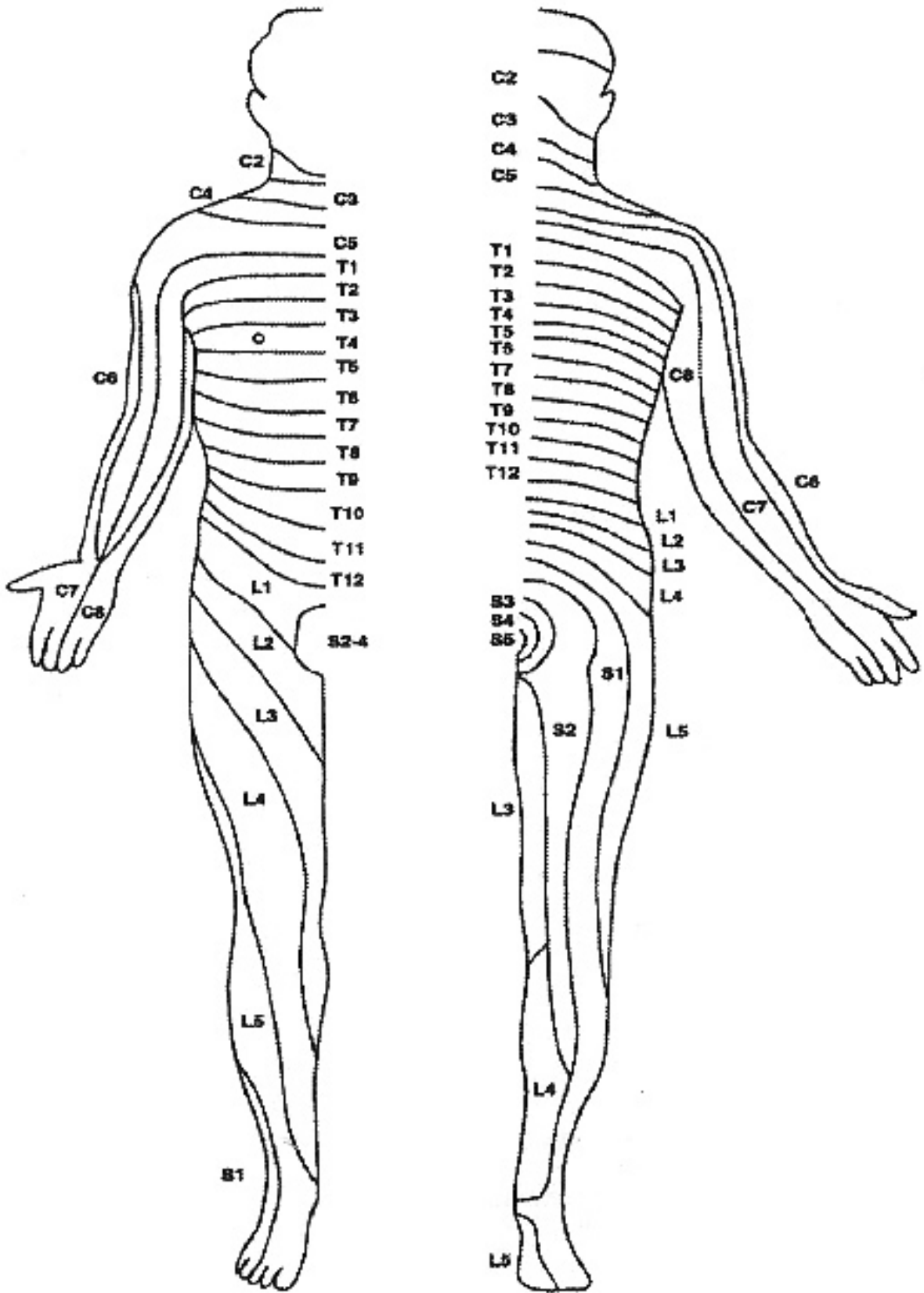
Mode of Transmission and Pathogenesis of Disease

During an episode of primary varicella infection (chickenpox), VZV is highly contagious and spread both by respiratory droplets (sneezing and coughing) and direct contact. Infection with VZV occurs when the virus comes into contact with the mucosa of the upper respiratory tract or the conjunctiva of the eye. The virus travels in the bloodstream via mononuclear cells to the skin, resulting in the generalized rash of chickenpox. The virus also infects human cells in the dorsal root ganglia of the spinal column and cranial nerve ganglia, where it becomes latent. Essentially protected from the human immune system, VZV typically remains dormant in the ganglia for decades.

Herpes zoster occurs when the virus subsequently reactivates, initially causing pain and soon

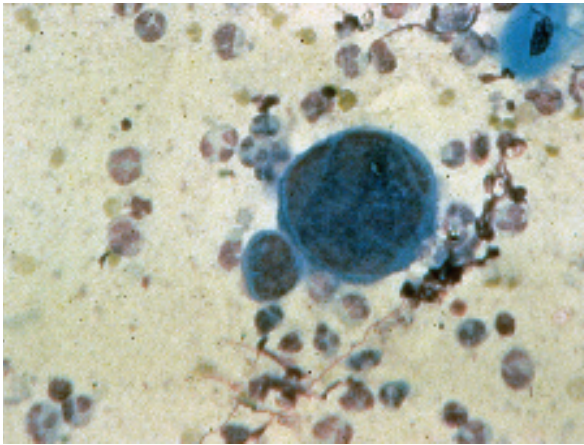
Herpes Zoster (Shingles) of the T5 Dermatome. The lesions are red, raised, fluid-filled vesicles or blisters that contain varicella-zoster virus. Note that these lesions are confined to a very specific area on one side of the chest. Photo by Howard Koh MD

Dermatomes.
 A dermatome is a segmental area of the skin innervated by fibers from a single dorsal nerve root of the spinal cord.
 Helpful hints:
 C6 (thumb),
 T10 (umbilicus),
 L5 (top of foot),
 S1 (bottom of foot).
 Courtesy of MGH



afterwards a vesicular rash in the distribution of one or two contiguous dermatomes. Herpes zoster is less contagious than varicella. Zoster generally spreads only by direct contact with open, draining lesions

and not via airborne droplets. This fragile virus can live for short periods of time on fomites such as towels, linens, and clothes. These items must be viewed as potential sources of transmission. Once



the lesions of shingles have crusted over and are no longer draining, the patient is no longer infectious.

Remember that a person with shingles cannot transmit zoster or shingles to others. However, contact with drainage from zoster lesions can cause chickenpox in individuals who have no history of prior varicella infection and have never had chickenpox.

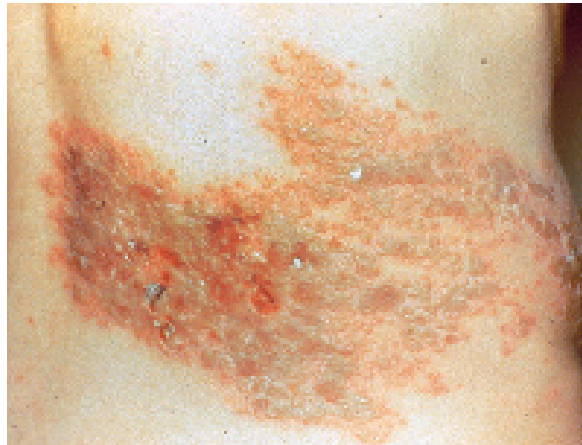Immunocompromised patients with zoster are at risk of developing widespread infection with VZV, called disseminated herpes zoster. This potentially serious illness may result in skin lesions over the entire body and infection of internal organs. This infection is thought to be more contagious than typical herpes zoster and may be spread by airborne droplets, as in primary varicella infection. For this reason, any patient with disseminated zoster, as well as those at risk for this infection, should be hospitalized with strict respiratory isolation.

Symptoms and Diagnosis

A prodrome of fever, malaise, and headache often precedes the vesicular eruption. Many patients experience pain and dysesthesias in the distribution of a sensory dermatome several days or weeks before the rash appears.

In immunocompetent individuals, the typical rash begins with groups of fluid-filled vesicles on a red or erythematous base. These are on one side of the body and limited to one or two dermatomes. The most commonly involved dermatomes are those innervated by the thoracic and lumbar nerves, and the ophthalmic branch of the trigeminal nerve. Crusting of the lesions usually occurs within ten days but may take as long as one month.

The diagnosis of herpes zoster is made clinically by the history of the prodrome, often with localized pain, and followed by the typical rash. Shingles can usually be differentiated from chickenpox and



herpes simplex on the basis of these characteristic symptoms and findings. Laboratory confirmation is necessary only in cases in which an atypical rash renders the diagnosis uncertain. Vesicular fluid can be examined by Tzanck smear, culture, polymerase chain reaction, or fluorescence microscopy.

Treatment

The goal of treatment of acute herpes zoster is to accelerate the healing of painful lesions and to prevent complications such as those mentioned in the next section. Many studies have examined the effects of antiviral therapy with acyclovir (Zovirax™), valacyclovir (Valtrex™), and famciclovir (Famvir™), all three of which are FDA-approved for the treatment of herpes zoster infection. The use of oral steroids in combination with antiviral therapy has also been studied. The evidence that any of these therapies is effective in preventing complications is limited, and no formal consensus for the use of these agents exists.

An acceptable approach is to withhold antiviral therapy from healthy adults under the age of 50 unless there is ophthalmic involvement or severe pain. Patients over the age of 50 should be treated with an antiviral agent. Antiviral agents are more effective if begun within 72 hours of the onset of symptoms. Some clinicians consider initiating therapy after this 72 hour window if new skin lesions continue to emerge. The mainstay of antiviral therapy for normal adults has been a 7-10 day course of acyclovir (Zovirax™) 800 mg PO five times per day. Valacyclovir (Valtrex™) 1000 mg PO TID and famciclovir (Famvir™) 500 mg PO TID have simpler dosing regimens and may be preferred for this reason.

Oral antiretrovirals are also effective in HIV positive patients with localized zoster infection. Because of the increased risk of relapse, treatment

(left) Multinucleated Giant Cell.

This Tzanck smear is from a scraping from the base of an unroofed blister. This microscopic finding of a multinucleated giant cell indicates the presence of a virus of the herpes family.

(right) Herpes Zoster (Shingles) of the T11-T12

Dermatomes. Several of the blisters have become crusted. Severe pain commonly accompanies this infection. Note that these lesions do not cross the mid-line. Photos by Howard Koh MD

should continue until all lesions have completely resolved. If dissemination occurs, intravenous therapy is indicated.

The addition of steroids to an antiviral regimen has not been proven to prevent post herpetic neuralgia, but should be considered in patients with severe pain in order to reduce the duration of acute symptoms. Steroids should not be used in patients with relative contraindications such as diabetes mellitus, gastritis, osteoporosis, or glaucoma.

Amitriptyline (Elavil™), a tricyclic antidepressant that has also been used to treat neuropathic pain, may decrease the risk of post herpetic neuralgia. A dose of 25 mg nightly, started within a couple days of the onset of the rash and continued for 90 days, has not been widely studied.

Pain control is a very important aspect in the treatment of this illness as well as zoster's most common complication, post herpetic neuralgia. Potential treatments to control pain include capsaicin ointment (Zostrix™), tricyclic antidepressants, gabapentin (Neurontin™), topical lidocaine, narcotics, and even regional nerve blocks.

Complications

Post herpetic neuralgia is the most common complication of herpes zoster, occurring in 10-15 percent of all patients. The risk of this complication increases with age. Post herpetic neuralgia is defined as sensory symptoms (usually pain or numbness) that exist in the distribution of the previously involved dermatome more than 30 days after the initial rash.

Herpes zoster ophthalmicus is another common complication. Caregivers should be aware that involvement of the ophthalmic branch of the trigeminal nerve is potentially sight-threatening. Evidence of this complication may include unilateral eye pain, vesicular eruption around the eye, conjunctivitis, episcleritis, iritis, or lid droop. Referral to an ophthalmologist must be made immediately.

Health care providers should monitor patients for signs of bacterial superinfection of skin lesions, which may require antibiotic therapy. Change in mental status, spread of skin lesions beyond two dermatomes, or involvement of the eyes should prompt immediate referral to specialists.

Prevention and Control

Herpes zoster is not as contagious as primary varicella infection (chickenpox). People who have had chickenpox in the past are considered immune

and are not at risk of developing shingles or chickenpox if exposed to a patient with shingles.

Persons who have never had primary varicella infection are at risk of developing chickenpox if they are exposed directly to the draining vesicles of shingles. For this reason, several precautions should be taken to decrease the risk to non-immune persons. Caregivers should wear gloves when examining the patient. Draining vesicles should be covered with a dressing until they have crusted over. Fomites, such as linens and clothes, may harbor the virus and should be handled with gloves. Once crusting of the vesicles occurs, there is no longer a risk of infectivity. If these precautions are taken, the risk to others in a shelter is minimal.

Pregnant women who are susceptible to VZV (have never had chickenpox) and are exposed to a patient with shingles should be referred for administration of varicella zoster immune globulin (VZIG) to decrease potential risk to the fetus.

Immunocompromised patients with herpes zoster are at high risk of developing disseminated disease, in which airborne spread is possible in addition to direct contact. Therefore, hospitalization and respiratory isolation should be considered in immunocompromised patients with localized or disseminated zoster.

Varicella vaccine is a live, attenuated vaccine against VZV that was licensed in 1995. It is contraindicated during pregnancy and is currently not recommended in HIV-infected individuals, although its safety in this population is under evaluation. Vaccination against VZV is currently recommended for the following susceptible adults (without a reliable history of chickenpox or a serologic test indicating immunity): health care workers, those with close contact to immunocompromised individuals or young children, and women who could become pregnant.

Special Considerations for Homeless Populations

While not proven by research studies at this time, psychological stress may be a risk factor for the development of herpes zoster. Although the prevalence of herpes zoster in homeless populations has not been specifically determined, the profound psychological stresses of homelessness may be associated with an increased risk of this condition in homeless persons, especially the elderly.

Summary

Herpes zoster results from reactivation of VZV, the same virus that causes chickenpox. The illness

is generally less severe than chickenpox, with painful skin lesions that are typically limited to one or two dermatomes.

Early treatment of localized zoster infection with antiretroviral medication is indicated in patients over the age of 50 or any patient with either ophthalmologic involvement or severe pain. Steroids, in addition to anti-retrovirals, may decrease the severity and duration of pain. Analgesia is an important aspect in the treatment of this painful infection.

Serious complications may arise from herpes zoster, including disseminated disease, ophthalmologic involvement, and infection of various organs. Immunocompromised individuals are at particular risk of complications. Immediate referral

to infectious disease specialists is indicated in these situations.

Patients with herpes zoster can transmit VZV to others via direct contact with draining skin lesions. Only people who have never had chickenpox are at risk, and the resulting illness is primary varicella infection (chickenpox). This risk becomes minimal in shelters if skin lesions are covered with dressings and gloves are worn when clothes and linens are handled. ■■

The author of this chapter gratefully acknowledges the invaluable contribution of Janet Groth, RN, MS, who authored this chapter in the original Manual.

Herpes Zoster Medication List		
Generic	Brand Name	Cost
acyclovir	Zovirax	\$
amitriptyline	Elavil	\$
capsaicin	Zostrix	\$
famciclovir	Famvir	\$\$\$
gabapentin	Neurontin	\$\$\$\$\$
valacyclovir	Valtrex	\$\$\$\$\$

References

- Albrecht MA. Clinical features of varicella-zoster infection: herpes zoster. UpToDate; 2002. <http://uptodate.com>
- Abrecht MA. Treatment and prevention of herpes zoster. UpToDate; 2002. <http://www.uptodate.com>
- Alper BS, Lewis PR. Does treatment of acute herpes zoster prevent or shorten postherpetic neuralgia? *Journal of Family Practice* 2000;49(3):255-264.
- Buchbinder SP, Katz MH, Hessel NA, et al. Herpes zoster and human immunodeficiency virus infection. *Journal of Infectious Diseases* 1992;166(5):1153-1156.
- Cohen JI, Brunell PA, Straus SE, et al. Recent advances in varicella-zoster virus infection. *Annals of Internal Medicine* 1999;130(11):922-932.
- Glesby M, Moore RD, Chaisson RE. Clinical spectrum of herpes zoster in adults infected with human immunodeficiency virus. *Clinical Infectious Diseases* 1995;21(2):370-375.
- Gnann JW, Whitley RJ. Clinical practice. Herpes zoster. *New England Journal of Medicine* 2002;347(5):340-346.
- Straus SE, Ostrove JM, Inchauspe G, et al. Varicella-zoster virus infections. Biology, natural history, treatment, and prevention. *Annals of Internal Medicine* 1988;108(2):221-237.